

Working Memory Capacities Neurally Dissociate: Evidence from Acute Stroke

Randi C Martin¹, Junhua Ding², A Cris Hamilton³, Tatiana T schnur^{2, 4}

1 Department of Psychological Sciences, Rice University, Houston, Texas, USA

2 Department of Neurosurgery, Baylor College of Medicine, Houston, Texas, USA

3 Department of Institution Reporting, Research and Information Systems, University of Texas at Austin, Austin, Texas, USA

4 Department of Neuroscience, Baylor College of Medicine, Houston, Texas, USA

Correspondence to:

Randi Martin, Psychology Dept.- MS25, PO. Box 1892; Rice University, Houston, Texas

77251, email: rmartin@rice.edu

Tatiana T. Schnur, Department of Neurosurgery, Baylor College of Medicine, One Baylor

Plaza, Houston, Texas 77030, USA, E-mail: tschnur@bcm.edu

Abstract

Substantial behavioral evidence implies the existence of separable working memory (WM) components for maintaining phonological and semantic information. In contrast, only a few studies have addressed the neural basis of phonological vs. semantic WM using functional neuroimaging and none has used a lesion-symptom mapping (LSM) approach. Here we address this gap, reporting a multivariate LSM study of phonological and semantic WM for 94 individuals at the acute stage of left hemisphere stroke. Testing at the acute stage avoids issues of brain reorganization and the adoption of patient strategies for task performance. The LSM analyses for each WM component controlled for the other WM component and semantic and phonological knowledge at the single word level. For phonological WM, the regions uncovered included the supramarginal gyrus, argued to be the site of phonological storage, and several cortical and subcortical regions plausibly related to inner rehearsal. For semantic WM, inferior frontal regions and the angular gyrus were uncovered. The findings thus provide converging evidence for separable systems for phonological and semantic WM that are distinguished from the systems supporting long-term knowledge representations in those domains.

Keywords: acute stroke, multivariate lesion-symptom mapping, phonological working memory, semantic working memory, support vector regression

Introduction

Models of working memory (WM) in the verbal domain typically focus on the maintenance of phonological information (e.g. Gupta and Tisdale 2009; Page and Norris 1998). For instance, the well-known working memory model of Baddeley and colleagues (Baddeley et al. in press) includes a phonological loop component, which consists of a buffer for maintaining phonological information and a rehearsal process that keeps this information active. However, considerable behavioral evidence from healthy and brain damaged individuals supports a multicomponent view of verbal WM, with separate buffers for maintaining phonological, semantic, and orthographic information (Martin et al. 1999; Shivde and Anderson 2011; see Martin et al. in press, for review). Consistent with the existence of separable WM capacities, the phonological and semantic components have been found to play different roles in sentence processing. The phonological component supports verbatim sentence repetition and speech rate in narrative production, whereas the semantic component supports the retention of word meanings prior to their integration across some distance during comprehension (e.g., maintaining the meaning of “cups” to integrate with the verb “cracked” in “Cups, vases, and mirrors cracked during the move”) and the elaboration of phrases during production (Martin and He 2004; Martin and Schnur 2019; Potter 2012; Tan and Martin 2018; Tan et al. 2019). In contrast to a wealth of behavioral data suggesting separable capacities, limited evidence from functional or structural neuroimaging is available regarding differential neural bases of semantic and phonological WM capacities. The present study addresses this issue by using a multivariate lesion-symptom mapping (LSM) approach (Zhang et al. 2014; Mirman et al. 2015; Yourganov et al. 2016; Lacey et al. 2017; Schumacher et al. 2019), relating performance on

tasks designed to tap semantic and phonological WM to the brain regions damaged in 94 individuals at the acute stage of left hemisphere (LH) stroke. Testing at the acute stage provides important advantages in lesion localization, as it avoids misinterpretation related to reorganization of function and the adoption of task strategies by the participants. By examining the relationship between lesion location and working memory performance, we demonstrate the brain regions required for phonological and semantic working memory, thus providing evidence as to the neural independence of working memory capacities. Below we summarize the current state of the literature regarding the brain basis of phonological and semantic WM.

Left Inferior Parietal Localization of Phonological WM

As with behavioral studies, studies of the neural basis of verbal WM have focused on phonological WM, typically using tasks tapping immediate memory for random digit or letter lists. Early findings using lesion overlap or functional neuroimaging supported the conclusion that phonological WM was supported by an inferior parietal region (with the greatest overlap in the supramarginal gyrus; Paulesu et al. 1993; Shallice and Vallar 1990), which is separate from lateral superior temporal regions involved in the phonological processes underlying speech perception and word production (e.g., accessing the sounds associated with word meanings in order to understand or produce speech; Price 2012; Turkeltaub and Coslett 2010).

More recently, however, some authors have argued that phonological WM is inextricably linked to our long-term knowledge of phonology (Martin and Saffran 1997) and presented evidence that the same temporal regions underlying phonological long-term knowledge support the temporary maintenance of phonological information (Ravizza et al.

2011; Leff et al. 2009). Such a view is consistent with embedded processes accounts of WM. Embedded processes accounts assume that, in general, WM consists of activated long-term knowledge representations together with a domain-general attentional system that brings some subset of activated information into the focus of attention (Cowan et al. in press). In the phonological domain, various criticisms can be raised of these studies which claim a dependence of WM on long-term phonological knowledge. In neuropsychological studies some have claimed that the mechanisms that support phonological WM are the same as those that support phonological processes even for tasks with little or no WM demand (such as judging whether a stimulus is a word or nonword or accessing the meaning of a word from spoken input; Belleville et al. 2003; Martin and Saffran 1997). However, the tests of phonological processing often made some demand on phonological WM (e.g., syllable discrimination across a filled delay; Martin and Saffran 1997). Furthermore, Martin and Breedin (1992) demonstrated that individuals who were matched in having mild phonological processing deficits (e.g., scoring slightly below the control range in making word/nonword judgments to stimuli such as “pickle” and “bickle”) varied widely on phonological WM tasks requiring maintenance of digit lists (e.g., repeating back a list of 5 digits), from severely impaired to within the control range, supporting independence between processing and WM maintenance. In recent lesion overlap studies with large sample sizes, some studies have failed to control for patient speech perception abilities (Baldo et al. 2012; Ghaleh et al. 2020) or have factored out performance on tasks that arguably depend on phonological WM (Leff et al. 2009). Since phonological WM tests depend on speech perception, the degree of speech perception deficit should relate to patients’ WM performance. Further, phonological WM should correlate with the degree of

damage to superior temporal regions based on the contribution of speech perception to performance on the WM task. The Leff et al. (2009) study controlled for nonword repetition which has been used as a measure of phonological WM capacity (e.g., Gathercole and Baddeley 1989), and thus its removal may have taken out a large portion of the variance due to phonological WM. Recently, in a large sample study of patients undergoing glioma resection, Pisoni et al. (2019) specifically contrasted phonological processing and WM regions and found only partial overlap between them, with damage to the supramarginal gyrus related only to WM. Thus, the neuropsychological evidence to date supporting a dependence of WM on long-term phonological knowledge is difficult to interpret given the methodological confounds.

Criticisms can also be raised with respect to fMRI studies claiming a reliance of phonological WM on phonological processing regions. One issue is that the speech perception regions have not typically been established in the same participants carrying out the phonological WM test, and sometimes the regions assumed to support phonological processing are remote from those indicated in meta-analyses of speech perception (e.g., Ravizza et al. 2011). Also, most studies have used visually rather than auditorily presented word lists (e.g., Ravizza et al. 2011; Lewis-Peacock et al. 2012). Although there is substantial evidence that visual verbal stimuli are recoded phonologically during WM tasks, one would expect more direct and consistent activation of phonological codes from auditory input. With visual input, participants may, at least on some trials, rely on memory for visual or orthographic features of the stimuli, reducing the sensitivity in detecting regions involved in phonological maintenance. Recently, Yue et al. (2018) carried out an fMRI study using a probe recognition task with auditorily presented lists of nonword

stimuli (e.g., list: treb, plim, suke; probe: trem). They found that the SMG showed activation and WM load effects during a delay period between the list and the probe whereas the superior temporal region identified for the same individuals as supporting speech perception did not. Moreover, using multivariate decoding methods (MVPA), phonological information could be decoded in the SMG irrespective of the classifier used whereas in the STG, decoding was successful for only one classifier, and moreover, decoding accuracy across individuals in the SMG correlated with their WM performance whereas decoding accuracy in the STG did not. In sum, the differential evidence for similar or different regions involved in phonological long-term knowledge vs. its maintenance may be the result of the use of tasks which did not strongly require phonological working memory, did not control for phonological input processing, or the assessment of phonological long-term knowledge using tasks that also required working memory.

Left Inferior Frontal Involvement in Semantic WM

In comparison to phonological WM, relatively little is known about the neural basis of semantic WM. Substantial evidence indicates that long-term semantic knowledge is represented in bilateral middle and inferior temporal lobes (e.g., Mummery et al. 1999; Visser et al. 2012). With regard to semantic WM, Martin (2005) noted that individuals identified as having semantic WM deficits had lesions encompassing left inferior frontal regions, which distinguished them from those with disruptions of semantic knowledge *per se* (Mummery et al. 1999) and from those with phonological WM deficits and inferior parietal lesions (Shallice and Vallar 1990). These findings would again argue against an embedded processes approach to WM. However, large sample studies of brain damaged

individuals have not been carried out examining the regions involved in semantic WM maintenance, while controlling for semantic knowledge deficits.

In early fMRI studies with healthy subjects, Martin et al. (2003) and Shivde and Thompson-Schill (2004) contrasted performance on short-term memory probe tasks tapping WM for phonological (rhyme or vowel probe) vs semantic (synonym probe) information (e.g., subjects heard a list of 1 or 4 words and, after a short delay, answered whether a probe stimulus was similar in rhyme/vowel/or meaning with one of the list words). Both reported that left parietal regions were more activated for the phonological than the semantic task whereas inferior/middle frontal regions were more activated for the semantic tasks. Hamilton et al. (2009) examined regions involved in maintaining word meanings prior to their integration in a task contrasting high and low demands on semantic WM. In this study, subjects judged whether adjectives could be sensibly integrated with a noun (e.g., green emerald vs. green sun). In the high WM demand condition, adjectives came before a noun (e.g., green, shining, bright emerald/sun) whereas in the low demand condition, the adjectives came after the noun (e.g., emerald/sun bright shining, green). The logic was that in the “before” condition, the meanings of the adjectives had to be maintained until the noun was processed, whereas in the “after” condition, each adjective could be integrated with the noun as it was perceived. Again, left inferior/middle frontal regions were more activated in the high than the low semantic WM demand condition. In an fMRI study using MVPA, Lewis-Peacock et al. (2012; Exp 2) found that semantic maintenance could be discriminated from phonological and visual maintenance in left anterior frontal and superior temporal regions. (It should be noted though that their stimuli were presented visually and the regions showing the greatest differentiation of

phonological from semantic and visual maintenance were in bilateral occipital lobes, suggesting that participants may have relied on orthographic coding to complete the supposedly phonological task.) In sum, there are only limited findings regarding the neural basis of semantic WM and those that exist tend to suggest the involvement of a left inferior frontal region.

Complicating Factors: Additional Regions Involved in Phonological and Semantic WM

The above findings are consistent with the claim of a contrast between left frontal regions supporting semantic WM and left parietal regions supporting phonological WM. However, this claim is complicated by other findings indicating a role for left frontal regions in articulatory rehearsal and a role of a left parietal region (i.e., the angular gyrus) in semantic processes (Binder et al. 2009). With regard to rehearsal, a long-standing assumption has been that subvocal articulatory rehearsal is used to support the maintenance of phonological forms (Baddeley et al. 1975), and rehearsal is a major component of the phonological loop in Baddeley et al.'s (in press) model. In the Yue et al. (2018) neuroimaging study, left frontal regions (including the precentral gyrus, posterior inferior frontal gyrus, and supplementary motor area) showed a load effect during the delay period of the phonological WM task. Previous imaging studies have provided evidence that these regions are involved in either subvocal rehearsal or executive processes related to motor planning (Chein and Fiez 2001; Smith et al. 1998). (In Yue et al. 2018, the putamen and cerebellum also showed load effects, and these regions are also likely involved in rehearsal given their role in controlling motor aspects of speech production.) With regard to left parietal regions' involvement in semantic maintenance,

many neuroimaging and neuropsychological studies have reported evidence that the angular gyrus (AG) plays an important role in semantic processing (Bemis and Pylkkanen 2013; Binder et al. 2009; Jefferies 2013; Price et al. 2015), with some of that evidence pointing to a role in semantic WM, given its contribution in integrating word meanings during phrase or sentence comprehension (e.g., Humphreys et al. 2007; Price et al. 2015). Yue et al. (2018) found evidence supporting a role for the AG in semantic WM as he showed that semantic representations could be decoded in the AG during the delay period of a semantic WM task, which involved judging the relatedness of word meanings across a delay.

Thus, there is strong evidence suggesting both a frontal-parietal dissociation for phonological vs. semantic working memory as well as the reverse. Although the frontal areas proposed to be involved in semantic WM (left inferior/middle frontal gyrus) differ from those proposed to be involved in subvocal articulatory rehearsal (left posterior inferior frontal, precentral gyrus, supplementary motor area), some of these areas overlap and are not clearly distinguished based on early fMRI results (e.g., LIFG involvement in rehearsal from Chein and Feiz 2001, and LIFG involvement in semantic WM from Shivde and Thompson-Schill 2004). Similarly, the left inferior supramarginal gyrus proposed to be involved in phonological WM is bordered by the left angular gyrus, which potentially plays a role in semantic WM and prior neuroimaging studies have not directly contrasted the roles of these two neighboring regions in semantic vs. phonological WM. Furthermore, given the ambiguities of determining the necessity of regions in cognitive processes based on neuroimaging results (e.g. Rorden and Karnath 2004), it is important to have converging lesion-based data to address necessity. Thus, the current study provides critical data

through examining the neural basis of semantic and phonological WM in the same subjects using a multivariate LSM approach where we have lesion coverage for these regions to determine if they can truly be differentiated regarding the type of WM that they support.

Current Study

To address the distinctiveness of the brain regions involved in phonological and semantic WM, we used multivariate LSM to relate disruption of phonological and semantic WM to brain damage in acute LH stroke, while controlling for individuals' single word phonological and semantic processing abilities. To test phonological WM, we used a digit matching span task, in which participants heard two lists of digits and decided whether they matched (Martin et al. 1994; Tan and Martin 2018). Digit lists were used as there is relatively little semantic information conveyed by random sets of digits. To test semantic WM, we used a category probe task in which participants judged whether a probe word was in the same semantic category as any list word (Martin et al. 1994; Tan and Martin 2018). Neither task required speech output, thus avoiding contributions of overt speech production deficits to WM performance. Both of these measures have been used in prior behavioral studies and have been found to relate to different aspects of language comprehension and production, as discussed earlier (e.g., Martin and He 2004). While these measures tap into different capacities, prior results have shown a significant correlation between them (Tan and Martin 2018; Tan et al. 2017), which is unsurprising in that an ability to retain phonological information would help to support performance on the category probe task. That is, even if semantic representations of the to-be-remembered items had been lost by the time the probe was presented, a surviving phonological record could be used to re-access semantics. In the other direction, there is evidence for a boost

from semantics, or at least familiarity, in digit span tasks, in that lists containing subsequences of digits that are more familiar (e.g., 1492) are better recalled (Jones and Macken 2015). Thus, to determine regions specific to one of the WM capacities we factored out performance on the other WM task in our analyses. In order to control for participants' speech perception and semantic knowledge, we also factored out performance on a picture-word matching task with semantically and phonologically related distractors (Martin and Schnur, 2019). To our knowledge this is the first study to examine the neural dissociation between phonological and semantic WM in a large group of persons with acute LH stroke while accounting for previous confounds of phonological input processing, semantic knowledge, the covariation between measures of the two capacities, and reorganization of function.

Materials and Methods

Participants

Ninety-four acute left hemisphere stroke patients (51 males; 81 right-handed; 86 ischemic stroke; 8 hemorrhagic stroke; age: $M = 61$ years; $S.D. = 12$ years; range = 25-85 years; education: $M = 14$ years; $S.D. = 4$ years; range = 0-33 years) were recruited from the Memorial Hermann, Houston Methodist and St. Luke's hospitals in Houston, Texas, USA, as part of an ongoing project (Martin and Schnur 2019; Ding et al. 2020). Subjects met the following inclusion criteria: Native English speaker; No other neurological diseases (e.g., tumor, dementia); No neuroradiological evidence of previous non-lacunar left hemisphere stroke (cf. Corbetta et al. 2015). Behavioral testing and clinical neuroimaging completed within one week after stroke (7 subjects within two weeks; median = 3 days, range = 1-12 days). We recruited 13 non-brain damaged participants as controls (three males; 11 right-

handed; age: $M = 55$ years; $S.D. = 14$ years; range = 37-78 years; education: $M = 16$ years; $S.D. = 3$ years; range = 12-22 years) matched to patients on demographic variables (age: $t(105) = -1.53, p = 0.13$; education: $t(86) = 1.66, p = 0.10$; handedness: $\chi^2 = 0.02, p = 0.88$). Informed consent was approved by the Baylor College of Medicine Institutional Review Board.

Behavioral tests

Phonological working memory. We measured phonological working memory (WM) with the digit matching span task (Allen et al. 2012; Martin and Schnur 2019; four participants completed the digit span task using the standard WAIS-R procedure, Wechsler and De Lemos 1981; Allen et al. 2012; Martin and Schnur 2019). With respect to digit matching span, participants first heard two-digit lists, in which one digit was presented per second. Participants judged (yes or no) whether the two lists were the same or not. In the ‘non-match’ trials, the second list reversed two adjacent digits. This reversed position was randomized. The list length increased from 2-6 digits, each including 6, 8, 6, 8, and 10 trials respectively. Half of the trials matched, half did not. We stopped testing when participants’ accuracy fell below 75% for a particular list length. We calculated the phonological WM span dependent measure for each list length by linear interpolation between the accuracy of two lists spanning 75% accuracy. If the accuracy of the two-digit list was lower than 75%, we assumed a 0-item list with 100% accuracy. If the accuracy of the six-digit list was higher than 75%, we assumed a 7-item list with 50% accuracy.

Semantic working memory. We measured semantic WM using the category probe task (Martin et al. 1994; Martin and Schnur 2019). Participants judged whether a spoken word was in the same semantic category as words in a preceding spoken list. We presented

words one per second. The categories included animals, body parts, clothing, fruit and kitchen equipment. The list length increased from 1 to 4 items, with 8, 8, 12 and 16 trials per list length, respectively. Half of the trials matched the lists' category and half not. The matched position in lists was randomized. We stopped task administration when participants' accuracy was below 75% for the penultimate list. Scoring proceeded as for digit span/digit matching span.

Phonological and semantic input processing. We measured the integrity of phonological and semantic input processing via a word picture matching task (Martin et al. 1999; Breese and Hillis 2004; Martin and Schnur 2019). We presented seventeen pictures four times. Each picture was presented with an auditorily presented matching word, phonologically related foil, semantically related foil and an unrelated foil, for a total of 68 trials distributed across four different presentation sets. Participants judged (yes/no, verbally or non-verbally) whether the picture and word represented the same object. We calculated phonological and semantic d' scores to estimate participants' ability to discriminate between matching trials, and phonological and semantic foil trials.

Image acquisition and preprocessing

We identified participants' lesions from diffusion weighted, T1, T2 FLAIR images (scanned in the axial direction) and for those contraindicated for MRI, CT scans.

Neuroimaging was collected within 1.5 days of behavioral testing (range 0-8 days). The resolution of diffusion-weighted and T1/T2 images was 1*1*4.5 mm and 0.5*0.5*4.5 mm, respectively and 0.5*0.5*5.0 mm for CT scans (n = 6 subjects).

To quantify patients' lesions, we first registered diffusion weighted images to T1/T2 images using AFNI (<https://afni.nimh.nih.gov/>). Then lesions were demarcated on the

diffusion weighted images using ITK-snap

(<https://www.itksnap.org/pmwiki/pmwiki.php>). Finally, we normalized T1/T2 and lesion images into the MNI space using ANTS (<https://stnava.github.io/ANTs/>; Avants et al. 2008). With regard to CT images, lesions were demarcated directly on the Colin-27 template while referring to CT images.

Multivariate LSM

To identify lesion location patterns associated with phonological and semantic WM, we conducted support-vector regression (SVR; libsvm 3; <https://www.csie.ntu.edu.tw/~cjlin/libsvm/>) LSM using MATLAB 2018b (<https://www.mathworks.com/products/matlab.html>). To control for potential confounding factors, we measured the relationship between brain damage location and either phonological or semantic WM performance independent of the contribution to performance from lesion size (cf. Sperber and Karnath 2018; DeMarco and Turkeltaub 2018), input processing deficits, and the opposing working memory ability. Specifically, we residualized working memory scores by lesion size (number of lesion mask voxels), the principal component analysis (PCA) composite measure of phonological and semantic input processing ($r = 0.69$; $p < 0.001$; explained variance = 85%; phonological input processing' loading = 0.92; semantic input processing's loading = 0.92) and the other WM score (WM measures were highly correlated: $r = 0.51$; $p < 0.001$). To note, we did not control for demographic variables because correlations with the two WM scores were not significant after multiple-comparison correction ($|r| < 0.25$; uncorrected $p > 0.03$). The residuals were further scaled to 0-1 to match the brain lesion range (0: intact; 1: lesioned). We only included voxels lesioned in at least 5 (5%) of 94 patients. Voxels with the same

lesion pattern across patients were combined as a patch (Pustina et al. 2018). We used all the patches to predict working memory residuals. A grid search was conducted to select the optimal parameters (cost: $0.01 - 10^9$ and gamma: 10^{-9} -1000; the same range as scikit-learn: <https://scikit-learn.org/stable/index.html>) for rbf-kernel SVR (Mirman et al. 2015). For each parameter combination, we used 5-fold cross-validation to acquire its mean square error of real and predicted dependent scores. We used 1000 permutations (shuffling dependent scores) to acquire the parameter combination significance level (the rank of the real model's mean square error in 1000 random models). The parameter pair with the lowest p value was considered the optimal combination which we then used in subsequent analysis. Finally, patterns of brain region damage significantly related to WM performance were determined via permutation test (1000 iterations) using the optimal parameter pair model (Zhang et al. 2014). The significance level of each patch was the rank of its beta value in beta values of 1000 random models. Only negative beta values were of interest (i.e., our expected direction). We set the significance threshold to $p < 0.05$ for models and patches. We defined brain regions based on the brain connectome atlas (Fan et al. 2016). The brain map was generated by REST (<http://www.restfmri.net/forum/>; Song et al. 2011). The insula was subdivided using a tripartite solution to be consistent with previous literature (Deen et al. 2010).

Results

Behavior

Compared with the non-brain damaged participants, patients showed significant impairments on phonological WM (span length scores; controls: $M = 6.12$, $S.D. = 0.50$, range = 5.00-6.38; patients: $M = 4.94$, $S.D. = 1.59$, range = 1.37-6.50; $t(55) = 5.48$, $p < 0.0001$),

semantic WM (span length scores; controls: $M = 4.59$, $S.D. = 0.80$, range = 3.35-5.45; patients: $M = 2.16$, $S.D. = 1.38$, range = 0.33-4.50; $t(23) = 9.22$, $p < 0.0001$), phonological input processing (d' scores; controls: $M = 3.70$, $S.D. = 0.19$, range = 3.44-3.78; patients: $M = 3.14$, $S.D. = 0.71$, range = -0.15-3.78; $t(92) = 6.69$, $p < 0.0001$) and semantic input processing (d' scores; controls: $M = 3.18$, $S.D. = 0.39$, range = 2.60-3.78; patients: $M = 2.70$, $S.D. = 0.74$, range = 0-3.78; $t(105) = 2.32$, $p = 0.02$; see Figure1).

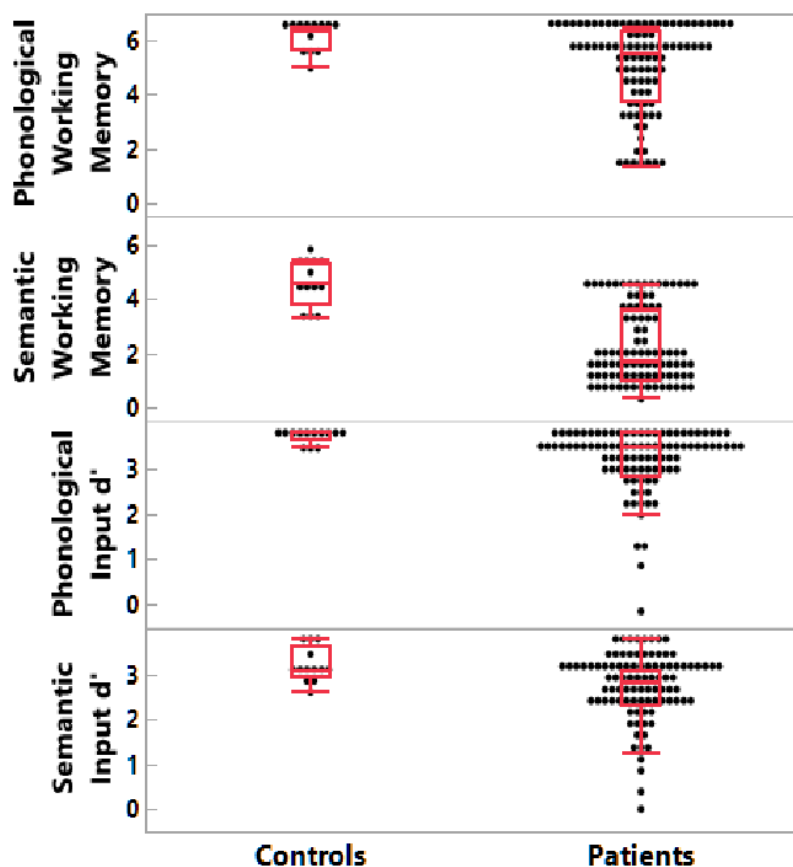


Figure 1. Patient and non-brain damaged control behavioral results. A) Phonological working memory span; B) Semantic working memory span; C) Phonological input processing; D) Semantic input processing.

Lesion distribution

Figure 2A displays lesion coverage across patients (lesion size: $M = 14098 \text{ mm}^3$, S.D. = 18641 mm^3 , range = $135\text{-}104243 \text{ mm}^3$). The primary damaged regions (regions damaged in at least five subjects and with > 100 lesioned voxels) included the middle and inferior frontal gyri, pre- and post-central gyri, superior temporal gyrus and sulcus, superior and inferior parietal lobules, insula, basal ganglia and thalamus. Figure 3 shows correlations between regional proportion damage and the distances between the damaged regions. Figure 3 reveals lower correlations in proportion damage between remote regions, indicating feasibility to test for functional dissociations between remote regions (e.g. SMG/ BA 39 vs IFG/ BA 44, 45). Moreover, not all adjacent damaged regions presented with higher correlations between proportion damage, indicating feasibility to test for functional dissociations between adjacent regions' functions (e.g. SMG/ BA 39 vs AG/ BA 40).

Notably, the primary regions damaged (with $n > 4$) did not include lateral aspects of the superior temporal gyrus thought to be involved in speech perception and the representation of phonetic features (Mesgarani et al. 2014; Turkeltaub and Coslett 2010) nor did they include middle and inferior temporal regions thought to represent semantic knowledge (Mummery et al. 1999; Visser et al. 2012). According to an embedded processes view of WM (Cowan et al. in press), persisting activation in such regions supports phonological and semantic WM. Regions beyond these would be those that underlie domain-general attentional processes. Thus, to the extent that our findings uncover regions specific to supporting either phonological or semantic WM, they would argue against the embedded processes view.

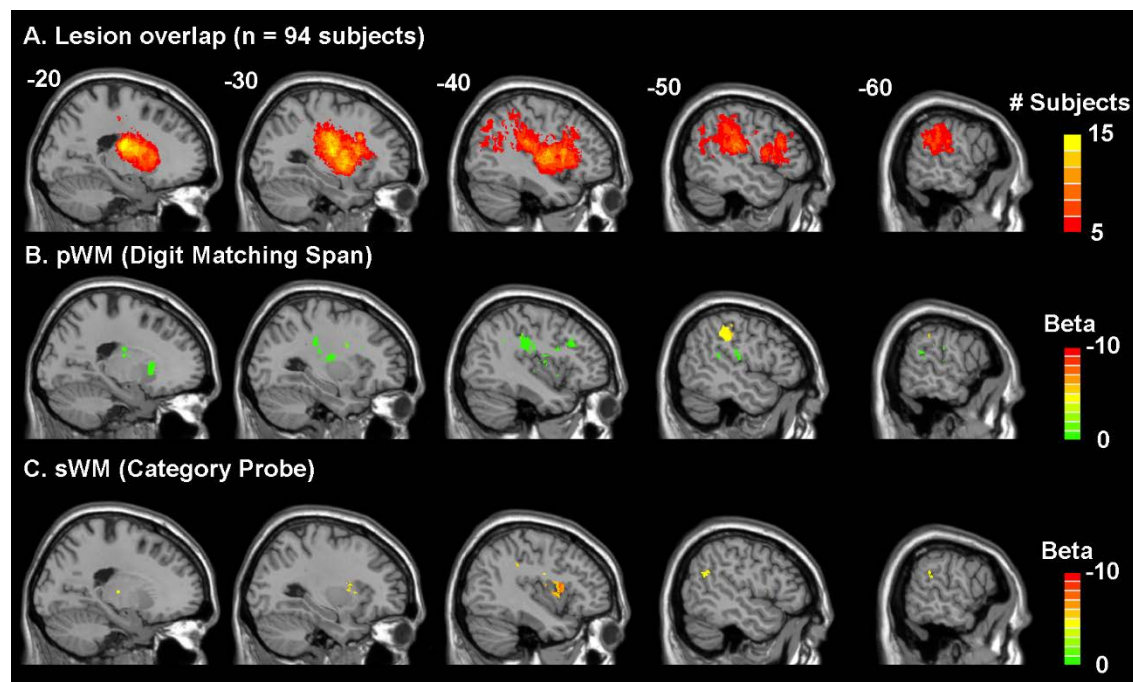


Figure 2. Lesion Overlap Distribution (A) and Lesion-Symptom Mapping Results (B & C). A) Lesion overlap in 94 acute left hemisphere stroke subjects where only regions damaged in at least five subjects ($> 5\%$) were included in the lesion-symptom mapping analyses. Figure 2B and Figure 2C show the beta values of the regions significantly associated with decreased performance in the phonological WM (Figure 2B) and semantic WM (Figure 2C) measures after accounting for lesion volume, input processing (input processing composite score of semantically- and phonologically related word-picture matching d' scores), and the respective opposing working memory task (p 's < 0.05). p/sWMM: phonological/semantic working memory.

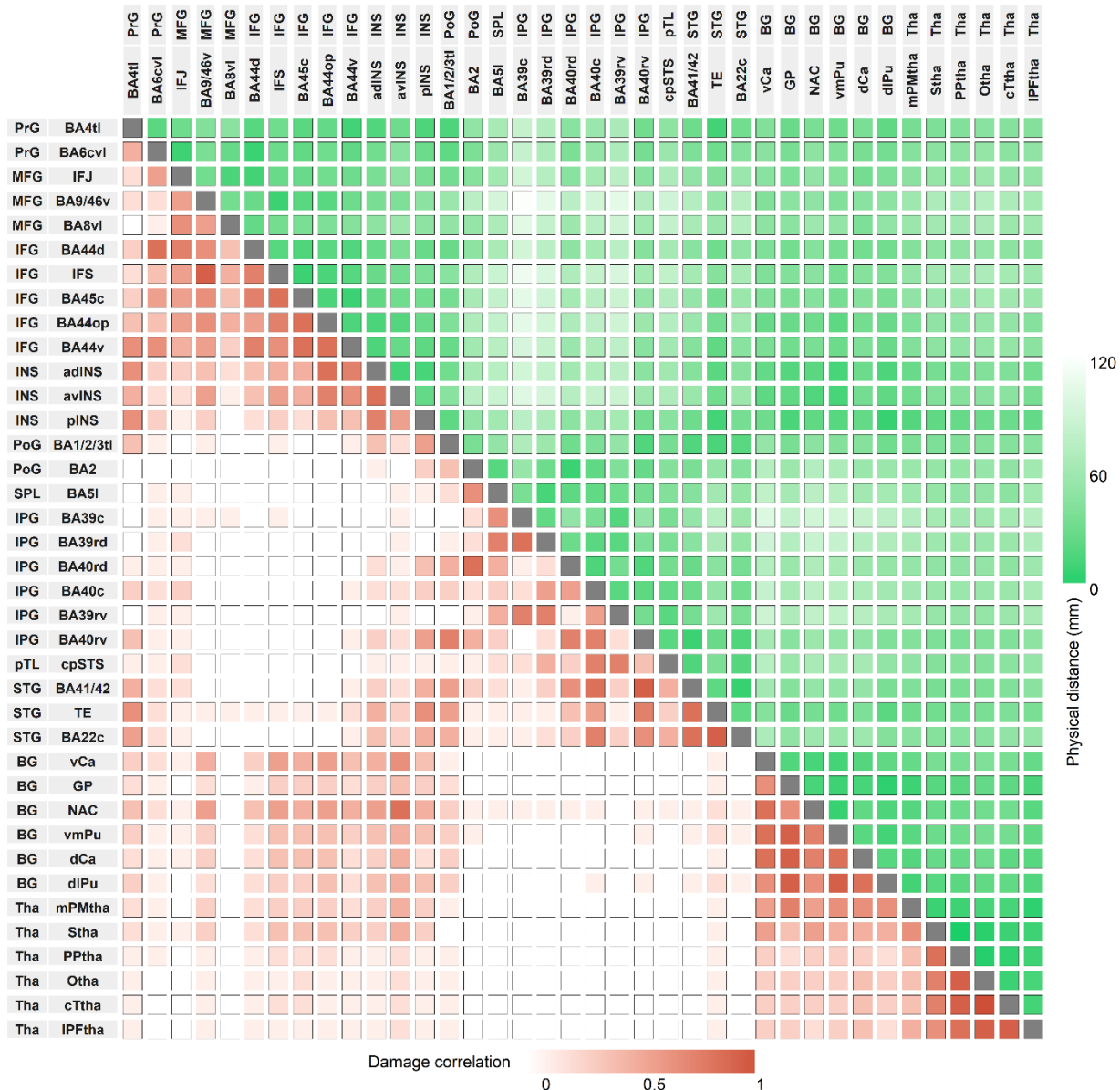


Figure 3. Matrix of between region damage correlations and distances. Increasing color intensity reflects either increasing correlations of proportion damage between regions (in red) or decreasing distance between regions (in green). PrG: precentral gyrus; MFG: middle frontal gyrus; IFG: inferior frontal gyrus; INS: insula; PoG: postcentral gyrus; SPL: superior parietal lobe; IPL: inferior parietal lobe; pTL: posterior temporal lobe; STG: superior temporal gyrus; BG: basal ganglia; Tha: thalamus; BA: Brodmann area; IFJ: inferior frontal junction; IFS: inferior frontal sulcus; STS: superior temporal sulcus; Ca: caudate; GP: globus pallidus; NAC: nucleus accumbens; Pu: putamen; PM: pre-

motor; S: sensory; PP: posterior parietal; O: occipital; PF: pre-frontal; tl: tongue and larynx region; c: caudal; v: ventral; d: dorsal; l: lateral; m: medial; a: anterior; p: posterior; op: opercular.

Lesion symptom mapping

Regarding the LSM, both the phonological and semantic WM models were statistically significant (phonological WM: cost = 10^{-8} , gamma = 10^{-8} , $p = 0.03$; semantic WM: cost = 0.1, gamma = 0.001, $p = 0.02$). Figure 2 and Table 1 display the brain regions whose damage (region size > 100mm³) significantly related to either phonological (Figure 2B) or semantic WM (Figure 2C). Because the models controlled for the other WM measure, brain regions significantly related to phonological and semantic WM performance were nonoverlapping.

Table 1. Lesion-Symptom Mapping Results

Lobe	Gyrus	Anatomical and Cyto-architectonic Descriptions	Phonological WM (mm ³)	Semantic WM (mm ³)
Frontal Lobe	Middle Frontal Gyrus	inferior frontal junction: junction of BAs 44 and 6/junction of inferior frontal sulcus and inferior pre-central sulcus	436	1
	Inferior Frontal Gyrus	opercular BA 44 (opercular inferior frontal gyrus)	0	233
Insular Lobe	Insular Gyrus	anterior dorsal insula	32	237
Parietal Lobe	Inferior Parietal Lobule	rostr dors BA 40 (supramarginal gyrus)	1129	49

		rostroventral BA 39 (angular gyrus)	110	325
		rostroventral BA 40	181	88
	Postcentral Gyrus	BA 1/2/3 (tongue and larynx region)	538	6
		BA 2	230	0
Temporal Lobe	Superior	BA 41/42: primary auditory cortex	209	29
	Temporal Gyrus			
	Posterior	caudoposterior superior	0	140
	Superior	temporal sulcus (BA 21, 37)		
	temporal Sulcus			
Subcortical Nuclei	Basal Ganglia	ventral caudate	168	0
		globus pallidus	102	0
		ventromedial putamen	377	0
		dorsal caudate	333	0
		dorsolateral putamen	137	0
	Thalamus	occipital thalamus	104	0
		lateral pre-frontal thalamus	187	9

Phonological and semantic WM lesion-symptom mapping results of regions with size > 100 mm³ significantly associated with these tasks in their respective lesion-symptom mapping analyses (p 's < 0.05). Lesion-symptom mapping analyses included regions damaged in at least five subjects (> 5%). WM: working memory.

With respect to phonological WM, the region of the largest size and with the greatest difference between phonological and semantic WM was in the rostr dors al BA 40 (with suggestion of extension rostroventrally, i.e., SMG; see Table 1), in line with prior findings (Shallice and Vallar 1990; Paulesu et al. 1993). Interestingly, while a region in the superior temporal gyrus related to phonological WM, the region was not in lateral aspects of the STG (BA 21, 22) related to speech perception, but instead in primary auditory cortex (BA 41,42). The other cortical regions specific to phonological WM are all plausibly related to rehearsal, including the inferior frontal junction (junction of BAs 44 and 6, a region joining the inferior frontal sulcus (between the IFG and MFG) and the inferior precentral sulcus), and the post-central gyrus (BAs 1, 2, 3), which includes tongue and larynx regions. A number of areas (basal ganglia and thalamus) were also found, all of which have been implicated in articulatory aspects of speech production (e.g., Bohland and Guenther 2006).

With respect to semantic WM, a region in a somewhat more anterior part of the left inferior frontal gyrus (opercular region of BA44) was obtained relative to that for phonological WM. A temporal lobe region bordering the posterior superior temporal sulcus (BA 21,37) was found, which is often implicated in the mapping from phonology to semantics (Okada and Hickok 2006; Wilson et al. 2018). As predicted, an inferior parietal region was obtained in BA39 (AG) which was thus differentiated from the inferior parietal SMG region obtained for phonological WM. The only other region related to semantic WM was the anterior dorsal aspect of the insula. While there is controversy regarding the functional roles of different subregions of the insula, some evidence suggests that anterior dorsal regions are involved in more cognitive processes, including semantic processing (Deen et al. 2010; Ardila et al. 2014)

Discussion

We examined whether damage to different brain regions caused phonological and semantic WM deficits in a large group of participants during the acute stage of stroke. We avoided the confound of reorganization of function while also controlling for the degree of phonological input processing and access to semantic knowledge. Multivariate lesion symptom mapping (LSM) revealed distinct regions underlying phonological and semantic WM. Although damage to both frontal and parietal lobules reduced WM capacity, the specific regions necessary for each WM capacity differed and did not include regions supporting phonological or semantic long-term knowledge. These results are consistent with a multicomponent view of WM, where functionally and anatomically distinct buffers maintain phonological and semantic information independent from the long-term memory of domain-specific representations.

Phonological WM

The region with the largest damage associated with reduced phonological WM in comparison to semantic WM was the supramarginal gyrus (SMG) in the inferior parietal lobe. Based on neuroimaging and neuropsychological findings, this SMG region has often been postulated to support the storage of phonological information (Paulesu et al. 1993; Shallice and Papagno 2019; Yue et al. 2018). Other frontal and subcortical regions related to phonological WM were, for the most part, regions carrying out articulatory and motor planning processes, most likely due to their involvement in subvocal rehearsal. Two frontal regions often ascribed a role in motor planning in functional neuroimaging studies (e.g., Chein and Fiez 2001) were also observed here (supplementary motor, posterior IFG). In addition, several subcortical regions were found, all of which have been implicated in

motor planning and motor control (Boland and Guenther 2006; Crosson et al. 2003). A few prior LSM studies have reported the involvement of subcortical regions (caudate in Leff et al. 2009, and caudate and putamen in Ivanova et al. 2018), but attributed their role to supporting executive functions involved in short-term memory performance. While we cannot rule out this possibility, both regions have also been found to be involved in simple tasks with little executive function demand involving the production of syllable sequences (Bohland and Guenther 2006). The current study uncovered a number of other subcortical regions not reported in other studies. It is possible that our research was able to detect the involvement of these regions due to testing at the acute stage, whereas other studies have been carried out at the chronic stage (Baldo et al. 2012; Ghaleh et al. 2020; Ivanova et al. 2018; Leff et al. 2009). There is evidence that individuals with subcortical lesions are likely to recover language functions (Demonet 1997; Heiss et al. 1999), thus, limiting the ability to detect the involvement of these regions in supporting phonological WM in a chronic sample.

Interestingly, reduced phonological WM capacity was also related to damage to sensory regions: 1) a somatosensory region representing the lips and larynx, and 2) primary auditory areas (Heschl's gyrus; BAs 41,42). If an fMRI study of WM revealed these activations, one might suppose that these were the consequence of implicit (or perhaps explicit) motor execution. Thus, one might hypothesize that these regions might be activated during rehearsal but were not necessary for it. However, in the LSM framework, the association of damage to these regions to reduced WM capacity suggests a necessary role. Such a necessary role might be accommodated on the grounds that a somatosensory target is needed to guide motor movements (or, in this case, covert motor movements

involved in rehearsal), a proposal that is consistent with the model of Walker and Hickok (2016), which bridges speech production and motor control models. In contrast, that damage to primary auditory regions reduced phonological WM capacity was somewhat more unexpected. A possible but unlikely explanation is that damage to such regions impaired speech perception, which played a greater role in phonological than semantic WM. However, it is unclear why that should be the case, since one might have expected the small set of digits to be more easily recognized than the words in the category probe task, which varied from trial to trial. More critically, the multivariate LSM analyses controlled for speech perception abilities, by factoring out performance on phonologically related trials in picture-word matching. Instead, we speculate that the involvement of primary auditory regions might be consistent with theories postulating that a match between articulatory and anticipated auditory targets is also used in modulating motor control (Hickok 2012). Overall, for phonological WM, the set of regions hang together as a network plausibly involved in phonological storage and covert rehearsal processes requiring motor planning and execution, though some questions remain regarding the role of the observed somatosensory and primary auditory regions.

Semantic WM

For semantic WM, damage to a smaller number of regions was associated with deficits. Previous neuropsychological and neuroimaging findings had suggested a critical role for the left inferior/middle frontal region. Although an inferior frontal and insular region was obtained, it was somewhat more posterior than anticipated based on prior fMRI results of semantic WM (Martin et al. 2003; Hamilton et al. 2009). The region that was uncovered (opercular LIFG, BA44) has been implicated in some studies as being involved in

semantic selection (Heim et al. 2009; Martin and Chao 2001) and in other studies as playing a role in a semantic maintenance process termed “refreshing” (Johnson et al. 2005; see subsequent section for further discussion). Lesion coverage was not extensive in more anterior aspects of the left inferior frontal and middle frontal gyri, thus limiting our ability to detect the involvement of more dorsal or anterior regions. In posterior areas, a parietal region in the AG (BA 39) and a pSTS region (BA21, 37) were obtained. Necessity of the AG for semantic WM is consistent with considerable neuroimaging evidence of its role in semantic processing and, specifically, in semantic integration – that is, the integration of word meanings (Binder et al. 2009; Humphries et al. 2006; Bemis and Pyllkanen 2013). Semantic integration (e.g., integrating noun-noun, “apple core”, and verb-noun, “throw dart”, combinations) would seem to necessarily draw on semantic WM to maintain the two concepts such that an appropriate integration could be carried out. With respect to the pSTS, damage to a similar pSTS locus after acute stroke in a subset of patients studied here was associated with reduced ability to produce nouns and increasingly complex word combinations during a narrative production task (Ding et al. 2020). In a behavioral analysis of another subset of these patients, semantic WM was necessary for producing increasingly complex word combinations (Martin and Schnur 2019). Elsewhere, a recent fMRI study investigating spoken and written narrative comprehension in non-brain damaged individuals (Wilson et al. 2019) revealed the involvement of specific subregions of the pSTS in phonological, lexical, and semantic processes. Based on their findings, they argued that the dorsal posterior region of the STS represented phonological and orthographic lexical representations, whereas the ventral posterior region supported higher level language processes involved in semantic and syntactic processing. Thus, one

might postulate that the pSTS region uncovered in the semantic WM task is required either for linking lexical phonological representations with semantic representations or with maintaining word meanings during phrase integration in comprehension and in holding several word meanings during phrase construction in production.

Thus, in general, our results converged with prior findings implicating the left inferior frontal gyrus (e.g., Martin et al. 2003; Lewis-Peacock et al. 2012; Shivde and Thompson-Schill 2004) and the angular gyrus (Humphries et al. 2006; Yue et al. 2018) in semantic WM. While the current findings cannot distinguish the role of these two regions, other findings in the literature suggest that the LIFG region is involved in retrieving or refreshing semantic representations (Heim et al. 2009; Johnson et al. 2005; Martin and Chao 2001), whereas the AG is involved more directly in maintaining semantic representations to support meaning integration (Humphries et al. 2006). The results showing the involvement of the pSTS are more novel but may underlie the maintenance of several word meanings during complex phrase construction (Ding et al. 2020). Further investigation is needed to determine if the engagement of this region replicates and what its distinctive role might be.

Rehearsal vs. Refreshing

As discussed previously, several regions involved in motor control and articulatory planning were found to support phonological WM performance, likely due to their involvement in inner rehearsal. Given that the LSM analyses controlled for the other WM component, these results imply that articulatory rehearsal processes were more important for performance on the phonological than the semantic WM task. In the behavioral literature on healthy adults, a separate process, termed refreshing, has been argued to keep

semantic representations in mind (e.g., Loiza and Camos 2018; Nishiyama 2018).

Refreshing is held to be a process by which recently activated representations are “rethought” and thereby given a boost of activation, with evidence suggesting independence of refreshing from both articulatory rehearsal and retrieval from long-term memory (Loiza and Camos 2018). Neuroimaging studies have suggested that left middle frontal regions are involved in refreshing semantic representations for words, though, in some experiments, BA44 and the insula were also involved (Johnson et al. 2005), coinciding with the left frontal regions found here. Thus, our findings are consistent with claims of different maintenance mechanisms for phonological and semantic WM.

Relation to Buffer vs. Embedded Process Theories of WM

As discussed in the introduction, some have argued that there are no dedicated regions for maintaining different types of representations in WM. According to the embedded processes view, persisting activations in regions devoted to long-term memory representations in that domain are thought to underlie WM (Cowan et al. 2020). Our findings for both phonological and semantic WM argue against this view. In the phonological domain, the embedded processes view would lead one to predict that lateral aspects of the STG (BA22), which have been found to underlie speech perception and the representation of sublexical phonological codes, would be critical to phonological WM. However, in our sample there were very few individuals with damage to such regions. Thus, while the present results cannot refute the possibility that lateral STG is a necessary component of the network involved in phonological WM, it is clear that it is not sufficient, as many of our patients had substantially impaired phonological WM capacity resulting from damage to regions elsewhere. In particular, a large region in the inferior parietal lobe

in the SMG was found to be related to phonological WM, consistent with prior studies implicating this region as a phonological store (e.g., Deschamps et al. 2014; Yue et al. 2018). Most other areas obtained were plausibly related to covert rehearsal (Boland and Guenther 2006; Chein and Fiez 2001), a process specific to maintaining phonological information in WM (Baddeley et al. in press; Loiza and Camos 2018). Although two sensory areas were obtained, these regions might also be engaged as part of the motor rehearsal process in providing sensory targets used to assess motor accuracy (Guenther et al. 2006; Hickock 2012; Walker and Hickok 2016).

In the semantic domain, we also observed varying degrees of impairment in semantic WM, even though our patients did not have damage to middle or inferior temporal regions thought to house long-term semantic representations for objects or to provide a semantic hub for linking together different aspects of concepts (Mesulam et al. 2015; Visser et al. 2012). Instead, the regions uncovered included frontal (BA44) and parietal regions (BA39), which are plausibly involved in retrieving, maintaining, and integrating semantic information (e.g., Helm et al. 2009; Humphries et al. 2006).

Conclusions

In summary, this study uncovered distinct regions involved in phonological and semantic WM, while controlling for phonological and semantic knowledge. Most regions that were identified in both domains were separate from regions postulated to be involved in regions representing long-term knowledge of phonology or semantics. Moreover, these results were obtained in a large sample of individuals at the acute stage of stroke, thus ruling out confounds due to reorganization of function. The organization of the regions involved in phonological WM seems fairly clear, consisting of regions involved in

phonological storage and motor processes involved in rehearsal (including regions representing sensori-motor targets for articulation). This is the first LSM study of semantic WM, and while distinct frontal and parietal regions were uncovered, future work will be needed to elucidate how these regions interact in supporting semantic WM.

Funding

This work was supported by an award to the Baylor College of Medicine from the National Institute on Deafness and Other Communication Disorders (R01DC014976).

Acknowledgements

The authors wish to thank Chia-Ming Lei, Danielle Rossi, and Miranda Brenneman for data collection. We gratefully acknowledge and thank our research subjects and their caregivers for their willingness to participate in this research. This work was presented at the Academy of Aphasia (2020).

References

- Allen CM, Martin RC, Martin N. 2012. Relations between short-term memory deficits, semantic processing, and executive function. *Aphasiology* 26(3-4):428-461.
- Ardila A, Bernal B, Rosselli M. 2014. Participation of the insula in language revisited: A meta-analytic connectivity study. *Journal of Neurolinguistics* 29:31-41.
- Avants BB, Epstein CL, Grossman M, Gee JC. 2008. Symmetric diffeomorphic image registration with cross-correlation: Evaluating automated labeling of elderly and neurodegenerative brain. *Medical Image Analysis* 12(1):26-41.
- Baddeley AD, Hitch GJ, Allen A. In press. A multicomponent model of working memory. In: Logie RH, Camos V, Cowan N, editors. *Working Memory: State of the Science*. Oxford, UK: Oxford University Press.
- Baddeley AD, Thomson N, Buchanan M. 1975. Word length and the structure of short-term memory. *Journal of Verbal Learning and Verbal Behavior* 14(6):575-589.

- Baldo JV, Katseff S, Dronkers NF. 2012. Brain regions underlying repetition and auditory-verbal short-term memory deficits in aphasia: Evidence from voxel-based lesion symptom mapping. *Aphasiology* 26(3-4):338-354.
- Belleville S, Caza N, Peretz I. 2003. A neuropsychological argument for a processing view of memory. *Journal of Memory and Language* 48(4):686-703.
- Bemis DK, Pylkkänen L. 2012. Basic Linguistic Composition Recruits the Left Anterior Temporal Lobe and Left Angular Gyrus During Both Listening and Reading. *Cerebral Cortex* 23(8):1859-1873.
- Binder JR, Desai RH, Graves WW, Conant LL. 2009. Where Is the Semantic System? A Critical Review and Meta-Analysis of 120 Functional Neuroimaging Studies. *Cerebral Cortex* 19(12):2767-2796.
- Bohland JW, Guenther FH. 2006. An fMRI investigation of syllable sequence production. *NeuroImage* 32(2):821-841.
- Breese EL, Hillis AE. 2004. Auditory comprehension: Is multiple choice really good enough? *Brain and Language* 89(1):3-8.
- Chein JM, Fiez JA. 2001. Dissociation of Verbal Working Memory System Components Using a Delayed Serial Recall Task. *Cerebral Cortex* 11(11):1003-1014.
- Corbetta M, Ramsey L, Callejas A, Baldassarre A, Hacker Carl D, Siegel Joshua S, Astafiev Serguei V, Rengachary J, Zinn K, Lang Catherine E et al. . 2015. Common Behavioral Clusters and Subcortical Anatomy in Stroke. *Neuron* 85(5):927-941.
- Cowan N, Morey CC, Naveh-Benjamin N. In press. An embedded-processes approach to working memory: how is it distinct from other approaches, and to what ends? In:

- Logie RH, Camos V, Cowan N, editors. Working Memory: State of the Science. Oxford, UK: Oxford University Press.
- Crosson B, Benefield H, Cato MA, Sadek JR, Moore AB, Wierenga CE, Gopinath K, Soltysik D, Bauer RM, Auerbach EJ et al. . 2004. Left and right basal ganglia and frontal activity during language generation: Contributions to lexical, semantic, and phonological processes. *Journal of the International Neuropsychological Society* 9(7):1061-1077.
- Deen B, Pitskel NB, Pelphrey KA. 2010. Three Systems of Insular Functional Connectivity Identified with Cluster Analysis. *Cerebral Cortex* 21(7):1498-1506.
- DeMarco AT, Turkeltaub PE. 2018. A multivariate lesion symptom mapping toolbox and examination of lesion-volume biases and correction methods in lesion-symptom mapping. *Human Brain Mapping* 39(11):4169-4182.
- Démonet JF. 1997. Subcortical Aphasia(s): A Controversial and Promising Topic. *Brain and Language* 58(3):410-417.
- Deschamps I, Baum SR, Gracco VL. 2014. On the role of the supramarginal gyrus in phonological processing and verbal working memory: Evidence from rTMS studies. *Neuropsychologia* 53:39-46.
- Ding J, Martin RC, Hamilton AC, Schnur TT. 2020. Dissociation between frontal and temporal-parietal contributions to connected speech in acute stroke. *Brain* 143(3):862-876.
- Fan L, Li H, Zhuo J, Zhang Y, Wang J, Chen L, Yang Z, Chu C, Xie S, Laird AR et al. . 2016. The Human Brainnetome Atlas: A New Brain Atlas Based on Connectional Architecture. *Cerebral Cortex* 26(8):3508-3526.

- Gathercole SE, Baddeley AD. 1989. Evaluation of the role of phonological STM in the development of vocabulary in children: A longitudinal study. *Journal of Memory and Language* 28(2):200-213.
- Ghaleh M, Lacey EH, Fama ME, Anbari Z, DeMarco AT, Turkeltaub PE. 2019. Dissociable Mechanisms of Verbal Working Memory Revealed through Multivariate Lesion Mapping. *Cerebral Cortex* 30(4):2542-2554.
- Guenther FH, Ghosh SS, Tourville JA. 2006. Neural modeling and imaging of the cortical interactions underlying syllable production. *Brain and Language* 96(3):280-301.
- Gupta P, Tisdale J. 2009. Does phonological short-term memory causally determine vocabulary learning? Toward a computational resolution of the debate. *Journal of Memory and Language* 61(4):481-502.
- Hamilton AC, Martin RC, Burton PC. 2009. Converging functional magnetic resonance imaging evidence for a role of the left inferior frontal lobe in semantic retention during language comprehension. *Cognitive Neuropsychology* 26(8):685-704.
- Heim S, Eickhoff SB, Friederici AD, Amunts K. 2009. Left cytoarchitectonic area 44 supports selection in the mental lexicon during language production. *Brain Structure and Function* 213(4):441-456.
- Heiss W-D, Kessler J, Thiel A, Ghaemi M, Karbe H. 1999. Differential capacity of left and right hemispheric areas for compensation of poststroke aphasia. *Annals of Neurology* 45(4):430-438.
- Hickok G. 2012. Computational neuroanatomy of speech production. *Nature Reviews Neuroscience* 13(2):135-145.

- Humphries C, Binder JR, Medler DA, Liebenthal E. 2006. Syntactic and Semantic Modulation of Neural Activity during Auditory Sentence Comprehension. *Journal of Cognitive Neuroscience* 18(4):665-679.
- Ivanova MV, Dragoy O, Kuptsova SV, Yu. Akinina S, Petrushevskii AG, Fedina ON, Turken A, Shklovsky VM, Dronkers NF. 2018. Neural mechanisms of two different verbal working memory tasks: A VLSM study. *Neuropsychologia* 115:25-41.
- Jefferies E. 2013. The neural basis of semantic cognition: Converging evidence from neuropsychology, neuroimaging and TMS. *Cortex* 49(3):611-625.
- Johnson MK, Raye CL, Mitchell KJ, Greene EJ, Cunningham WA, Sanislow CA. 2005. Using fMRI to investigate a component process of reflection: Prefrontal correlates of refreshing a just-activated representation. *Cognitive, Affective, & Behavioral Neuroscience* 5(3):339-361.
- Jones G, Macken B. 2015. Questioning short-term memory and its measurement: Why digit span measures long-term associative learning. *Cognition* 144:1-13.
- Lacey EH, Skipper-Kallal LM, Xing S, Fama ME, Turkeltaub PE. 2017. Mapping Common Aphasia Assessments to Underlying Cognitive Processes and Their Neural Substrates. *Neurorehabilitation and Neural Repair* 31(5):442-450.
- Leff AP, Schofield TM, Crinion JT, Seghier ML, Grogan A, Green DW, Price CJ. 2009. The left superior temporal gyrus is a shared substrate for auditory short-term memory and speech comprehension: evidence from 210 patients with stroke. *Brain* 132(12):3401-3410.

- Lewis-Peacock JA, Drysdale AT, Oberauer K, Postle BR. 2012. Neural Evidence for a Distinction between Short-term Memory and the Focus of Attention. *Journal of Cognitive Neuroscience* 24(1):61-79.
- Loaiza VM, Camos V. 2018. The role of semantic representations in verbal working memory. *J Exp Psychol Learn Mem Cogn* 44(6):863-881.
- Martin A, Chao LL. 2001. Semantic memory and the brain: structure and processes. *Current Opinion in Neurobiology* 11(2):194-201.
- Martin N, Saffran EM. 1997. Language and Auditory-verbal Short-term Memory Impairments: Evidence for Common Underlying Processes. *Cognitive Neuropsychology* 14(5):641-682.
- Martin RC. 2005. Components of Short-Term Memory and Their Relation to Language Processing: Evidence From Neuropsychology and Neuroimaging. *Current Directions in Psychological Science* 14(4):204-208.
- Martin RC, Breedin SD. 1992. Dissociations between speech perception and phonological short-term memory deficits. *Cognitive Neuropsychology* 9(6):509-534.
- Martin RC, He T. 2004. Semantic short-term memory and its role in sentence processing: A replication. *Brain and Language* 89(1):76-82.
- Martin RC, Lesch MF, Bartha MC. 1999. Independence of Input and Output Phonology in Word Processing and Short-Term Memory. *Journal of Memory and Language* 41(1):3-29.
- Martin RC, Purcell J, Rapp B. In press. Domain-specific working memory: Perspectives from cognitive neuropsychology. In: Logie RH, Camos V, Cowan N, editors. *Working Memory: State of the Science*. Oxford, UK: Oxford University Press.

- Martin RC, Schnur TT. 2019. Independent contributions of semantic and phonological working memory to spontaneous speech in acute stroke. *Cortex* 112:58-68.
- Martin RC, Shelton JR, Yaffee LS. 1994. Language Processing and Working Memory: Neuropsychological Evidence for Separate Phonological and Semantic Capacities. *Journal of Memory and Language* 33(1):83-111.
- Martin RC, Wu D, Freedman M, Jackson EF, Lesch M. 2003. An event-related fMRI investigation of phonological versus semantic short-term memory. *Journal of Neurolinguistics* 16(4):341-360.
- Mesgarani N, Cheung C, Johnson K, Chang EF. 2014. Phonetic Feature Encoding in Human Superior Temporal Gyrus. *Science* 343(6174):1006-1010.
- Mesulam M-M, Thompson CK, Weintraub S, Rogalski EJ. 2015. The Wernicke conundrum and the anatomy of language comprehension in primary progressive aphasia. *Brain* 138(8):2423-2437.
- Mirman D, Zhang Y, Wang Z, Coslett HB, Schwartz MF. 2015. The ins and outs of meaning: Behavioral and neuroanatomical dissociation of semantically-driven word retrieval and multimodal semantic recognition in aphasia. *Neuropsychologia* 76:208-219.
- Mummery CJ, Patterson K, Wise RJS, Vandenberg R, Price CJ, Hodges JR. 1999. Disrupted temporal lobe connections in semantic dementia. *Brain* 122(1):61-73.
- Nishiyama R. 2018. Separability of active semantic and phonological maintenance in verbal working memory. *PLOS ONE* 13(3):e0193808.
- Okada K, Hickok G. 2006. Identification of lexical-phonological networks in the superior temporal sulcus using functional magnetic resonance imaging. *NeuroReport* 17(12):1293-1296.

- Page MP, Norris D. 1998. The primacy model: a new model of immediate serial recall. *Psychological review* 105(4):761-781.
- Paulesu E, Frith CD, Frackowiak RS. 1993. The neural correlates of the verbal component of working memory. *Nature* 362(6418):342-345.
- Pisoni A, Mattavelli G, Casarotti A, Comi A, Riva M, Bello L, Papagno C. 2019. The neural correlates of auditory-verbal short-term memory: a voxel-based lesion-symptom mapping study on 103 patients after glioma removal. *Brain Structure and Function* 224(6):2199-2211.
- Potter M. 2012. Conceptual Short Term Memory in Perception and Thought. *Frontiers in Psychology* 3(113).
- Price AR, Bonner MF, Peelle JE, Grossman M. 2015. Converging Evidence for the Neuroanatomic Basis of Combinatorial Semantics in the Angular Gyrus. *The Journal of Neuroscience* 35(7):3276-3284.
- Price CJ. 2012. A review and synthesis of the first 20years of PET and fMRI studies of heard speech, spoken language and reading. *NeuroImage* 62(2):816-847.
- Pustina D, Avants B, Faseyitan OK, Medaglia JD, Coslett HB. 2018. Improved accuracy of lesion to symptom mapping with multivariate sparse canonical correlations. *Neuropsychologia* 115:154-166.
- Ravizza SM, Hazeltine E, Ruiz S, Zhu DC. 2011. Left TPJ activity in verbal working memory: Implications for storage- and sensory-specific models of short term memory. *NeuroImage* 55(4):1836-1846.
- Rorden C, Karnath H-O. 2004. Using human brain lesions to infer function: a relic from a past era in the fMRI age? *Nature Reviews Neuroscience* 5(10):812-819.

- Schumacher R, Halai AD, Lambon Ralph MA. 2019. Assessing and mapping language, attention and executive multidimensional deficits in stroke aphasia. *Brain* 142(10):3202-3216.
- Shallice T, Papagno C. 2019. Impairments of auditory-verbal short-term memory: Do selective deficits of the input phonological buffer exist? *Cortex* 112:107-121.
- Shallice T, Vallar G. 1990. The impairment of auditory-verbal short-term storage. *Neuropsychological impairments of short-term memory*:11-53.
- Shivde G, Anderson MC. 2011. On the existence of semantic working memory: evidence for direct semantic maintenance. *J Exp Psychol Learn Mem Cogn* 37(6):1342-1370.
- Shivde G, Thompson-Schill SL. 2004. Dissociating semantic and phonological maintenance using fMRI. *Cognitive, Affective, & Behavioral Neuroscience* 4(1):10-19.
- Smith EE, Jonides J, Marshuetz C, Koeppel RA. 1998. Components of verbal working memory: Evidence from neuroimaging. *Proceedings of the National Academy of Sciences* 95(3):876-882.
- Song X-W, Dong Z-Y, Long X-Y, Li S-F, Zuo X-N, Zhu C-Z, He Y, Yan C-G, Zang Y-F. 2011. REST: a toolkit for resting-state functional magnetic resonance imaging data processing. *PloS one* 6(9):e25031.
- Sperber C, Karnath H-O. 2018. On the validity of lesion-behaviour mapping methods. *Neuropsychologia* 115:17-24.
- Tan Y, Martin RC. 2018. Verbal short-term memory capacities and executive function in semantic and syntactic interference resolution during sentence comprehension: Evidence from aphasia. *Neuropsychologia* 113:111-125.

- Tan Y, Martin RC, Van Dyke JA. 2017. Semantic and Syntactic Interference in Sentence Comprehension: A Comparison of Working Memory Models. *Frontiers in Psychology* 8(198).
- Turkeltaub PE, Branch Coslett H. 2010. Localization of sublexical speech perception components. *Brain and Language* 114(1):1-15.
- Visser M, Jefferies E, Embleton KV, Ralph MAL. 2012. Both the Middle Temporal Gyrus and the Ventral Anterior Temporal Area Are Crucial for Multimodal Semantic Processing: Distortion-corrected fMRI Evidence for a Double Gradient of Information Convergence in the Temporal Lobes. *Journal of Cognitive Neuroscience* 24(8):1766-1778.
- Walker GM, Hickok G. 2016. Bridging computational approaches to speech production: The semantic–lexical–auditory–motor model (SLAM). *Psychonomic Bulletin & Review* 23(2):339-352.
- Wechsler D, De Lemos MM. 1981. Wechsler adult intelligence scale-revised. Harcourt Brace Jovanovich.
- Wilson SM, Bautista A, McCarron A. 2018. Convergence of spoken and written language processing in the superior temporal sulcus. *NeuroImage* 171:62-74.
- Yourganov G, Fridriksson J, Rorden C, Gleichgerricht E, Bonilha L. 2016. Multivariate Connectome-Based Symptom Mapping in Post-Stroke Patients: Networks Supporting Language and Speech. *The Journal of Neuroscience* 36(25):6668-6679.
- Yue Q, Martin RC, Hamilton AC, Rose NS. 2018. Non-perceptual Regions in the Left Inferior Parietal Lobe Support Phonological Short-term Memory: Evidence for a Buffer Account? *Cerebral Cortex* 29(4):1398-1413.

Zhang Y, Kimberg DY, Coslett HB, Schwartz MF, Wang Z. 2014. Multivariate lesion-symptom mapping using support vector regression. *Human Brain Mapping* 35(12):5861-5876.